

Er,Cr:YSGG laser for cavity preparation

A case presentation

Author_Dr Ralf Borchers, Germany

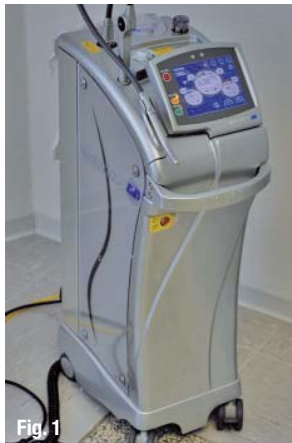

Fig. 1

Fig. 1_BIOLASE Waterlase MD Turbo.

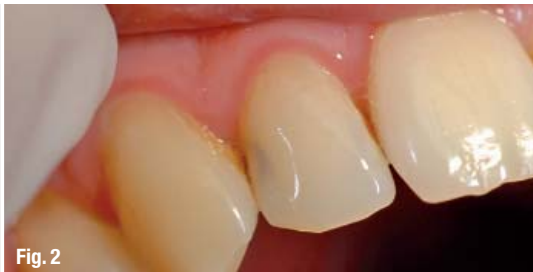

Fig. 2

Fig. 2_Upper right lateral incisor with caries.

Fig. 3_Turbo handpiece with MX7 tip.

Fig. 4_Preparation of enamel.

_Introduction

In the early 1990s, cavity preparation by Er:YAG laser was an exercise in patience. Owing to the low peak power of the pulse and a slow frequency the cavity was finished in what felt like hours after starting the laser treatment. Today, short pulse length, high power and increased frequency lead to short treatment times, comparable with conventional mechanical treatment by burs. Nearly all kinds of preparation and caries excavation can be done without any anaesthesia if the dentist is familiar with his laser and the correct treatment options. The procedure itself is more comfortable for the patient because there is no pressure or vibration on the tooth owing to the non-contact mode of the treatment. Additionally, the bactericidal effect of the laser results in a nearly sterile cavity without any smear layer, which in the case of direct or indirect pulp capping speeds up healing and helps to avoid eventual endodontic treat-

ment of the tooth. Laser treatment of cavities can be done minimally invasively with maximum preservation of sound tissue and even selective removal of caries is possible if the dentist is well versed. Subsequently, a cavity and caries treatment will be explained to demonstrate the procedure.

_Case presentation

The patient was a 28-year-old man with a carious lesion at the upper lateral incisor on the right side (Fig. 2). Laser treatment was done with a Waterlase MD Turbo (BIOLASE), an Er,Cr:YSGG laser with a wavelength of 2,780 nm (Fig. 1) and a turbo handpiece with a MX7 fibre tip (Fig. 3). The treatment was done without any anaesthesia and began with the preparation of the cavity. In case of interdental cavities the use of the „gold handpiece“ with longer tips would be preferable. Using the longer tips increases the ability to reach deeper zones in the mesial or distal part of the cavity and prevents from harming the adjacent tooth. Because of the different form of the tip and handpiece the speed of ablation will drop down slightly in this case.

Enamel treatment was done with the following parameters: 6.25 W, 30 Hz, 140 μ s pulse, 75% water, 90% air (Fig. 4). Treatment of caries and dentine was done with the following parameters: 3 W, 30 Hz, 140 μ s pulse, 35% water, 45% air (Fig. 5). During the procedure, the treated area was marked by the ablated enamel, a white surface looking nearly already etched (Fig. 6). The complete procedure was done in non-contact mode; therefore, the cavity had to be probed occasionally to ensure caries removal because the usual tactile feeling is absent during hard-tissue laser treatment. After cavity preparation and caries removal, the lased surface was treated with an excavator to remove the loosened enamel particles and thereby avoid a white area shining through the filling surface. The tooth was subsequently etched



Fig. 3

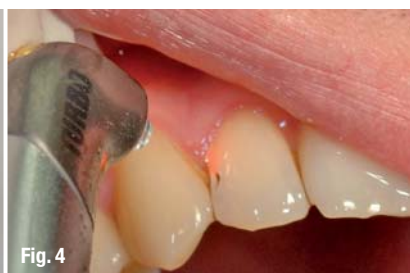

Fig. 4

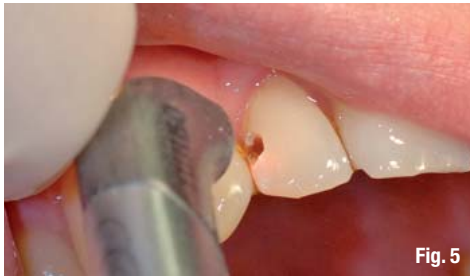

Fig. 5

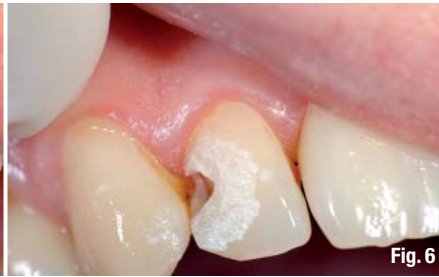

Fig. 6

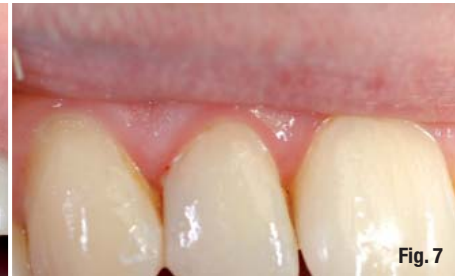

Fig. 7

and bonded as with conventional treatment. The finished filling after polishing is shown in Figure 7.

Summary

The entire procedure was done in ten minutes. No change of instruments was necessary, so as in classical treatment and therefore only a minimum of instruments have to be cleaned and sterilised. Due to laser preparation and additional etching the long term prognosis for such fillings is very high, which could be proved already by clinical studies and dye penetration tests. Patients compliance is very high for laser treatment because the entire procedure is more comfortable and mostly painfree. There is no vibration or pressure on the tooth, no injection for anesthesia is needed and treatment is accomplished in a short time. Sometimes its

possible to finish the complete procedure in the time another conventional treated patient is still waiting for anesthesia success. Last but not least it has to be mentioned that more than 90% of the already laser treated patients are asking for laser treatment the next time although they know about the additional charging of the laser treatment.

contact

laser

Dr Ralf Borchers


Bahnhofstrasse 14, 32257 Bünde, Germany
Tel: +49 5223 10222

Dr.Borchers@praxis-borchers.de
www.laserdentistry-germany.de

AD

LaserHF®

Laser meets Radio Frequency



LaserHF®

Worldwide first combined Laser plus HF unit

- Pre-adjusted programs for all dental soft tissue treatments, with individual programming
- Easy handling by dual operating concept: touch-screen and automatic starting system
- Modern radio frequency surgery (2.2 MHz) allows easy, fast and precise cutting
- Diode laser (975 nm) for periodontology, endodontology and implant exposure
- Therapeutic laser (650 nm) for Low Level Laser Therapy (LLLT) and antimicrobial Photodynamic Therapy (aPDT)
- Good value of money

www.hagerwerken.de

Tel. +49 (203) 99269-26 · Fax +49 (203) 299283

HÄGER
WERKEN